

## Male Infertility – Modern Diagnostic and Treatment Modes

a report by

**Panayiotis M Zavos, PhD, EdS**

*Professor Emeritus of Reproductive Physiology/Andrology, University of Kentucky, Director, Andrology Institute of America and Associate Director, Kentucky Center for Reproductive Medicine & IVF*



Panayiotis M Zavos, PhD, EdS, is Professor Emeritus of Reproductive Physiology/ Andrology at the University of Kentucky, Director of the Andrology Institute of America, and Associate Director of the Kentucky Center for Reproductive Medicine and IVF in Lexington. He received the Distinguished Alumnus Award and the Graduate Teaching Award from Emporia State University and the Student Leadership Award from the University of Minnesota. Dr Zavos has a long career as a reproductive specialist and has devoted more than 25 years to academia and research. He has authored or co-authored more than 400 peer-review publications, along with a number of solicited reviews, book chapters and popular press releases. He is a member of the American Society for Reproductive Medicine (ASRM), the American Society of Andrology (ASA), the European Society for Human Reproduction and Embryology (ESHRE), the Middle East Fertility Society (MEFS), the Japanese Fertility Society, and the International Society of Cryobiology among others. Dr Zavos received his BS in Biology-Chemistry in 1970, his MS in Biology-Physiology in 1972 and Education Specialist in Science (EdS) in 1976 from Emporia State University in Kansas. He earned his PhD in Reproductive Physiology, Biochemistry and Statistics in 1978 from the University of Minnesota.

### Background

Infertility is defined as the inability to achieve pregnancy after one year of unprotected intercourse. An estimated 15% of couples meet this criterion and are considered infertile. Historically, the work-up for the infertile couple focused primarily on conditions of the female. Conditions of the male are estimated to account for nearly 30% of infertility cases and conditions of both the female and the male account for another 20%. Conditions of the male that affect fertility are still under-diagnosed and under-treated.

In general, causes of infertility in men can be explained by deficiencies in ejaculate volume, sperm concentration or too few sperm (oligospermia), complete absence of sperm in the ejaculate (azoospermia), sperm motility (asthenospermia), or sperm morphology (teratospermia). Nearly 70% of conditions causing infertility in men can be diagnosed by history, physical examination, testicular volume estimation, and hormonal and semen analysis. A rational approach is necessary to perform the appropriate work-up and to choose the best treatment options for the couple.

Technological advancements in assisted reproduction technologies (ART) make conceiving a child possible with as little as one viable sperm and one egg. While the work-up traditionally has been delayed until a couple has been unable to conceive for 12 months, beginning the work-up at the first visit is now recommended because of a recent trend towards delaying family planning. This article summarizes current knowledge of causes of infertility in men and describes its work-up, and treatment modes.

### Evaluation of the Male Patient

The evaluation of the male patient is three-fold:

- detailed history taking;
- physical examination; and
- routine laboratory testing, including semen analysis.

### History

The evaluation of the male patient begins with a thorough history, including duration of the problem, sexual habits, prior pregnancies and previous treatment, as well as the general health of the patient. A childhood or developmental history along with the patient's medical and surgical history should be discussed, including items such as a history of diabetes, prostate surgery, or hernia repairs. Exposure to possible toxic agents such as radiation, heavy metals, and organic solvents should also be included.

Numerous publications have shown that smoking negatively affects male fertility in terms of sperm characteristics, sexual frequency and sexual satisfaction.<sup>1-3</sup> If both the male and female smoke, there is also an additive effect.<sup>4</sup> It has been shown via electron microscopy that smoking causes damage to the ultrastructure of the axoneme of human spermatozoa.<sup>3</sup> Patients that smoke should be advised to stop smoking prior to any further infertility treatment.

More recently, it has been shown, for the first time, that there is an aging effect on not only sexual behavioral characteristics but also on the seminal and sperm characteristics.<sup>5</sup> The sperm parameter most commonly

1. Zavos P M, Correa J R, Karagounis C S et al., "An electron microscope study of the axonemal ultrastructure in human spermatozoa from smoking and nonsmoking males", *Fertil. Steril.* (1998);69: pp. 430-444.
2. Zavos P M, Correa J R, Antypas S, Zarmakoupis Zavos P N, "The effects of seminal plasma from cigarette smokers on sperm viability and longevity", *Fertil. Steril.* (1998);69: pp. 425-429.
3. Zavos P M, Zarmakoupis C N, Zarmakoupis Zavos P N, "The impact of cigarette smoking on human reproduction: its effects on female and male fecundity", *Mid. East Fertil. Soc. J.* (1998);3: pp. 340-347.
4. Zavos P M, Kaskar K, Correa J R, Aslanis P, Koundouros S, "The impact of cigarette smoking on male and female sexual behavior: Who sets the pace?", *Asian J. Androl.* (2005) (in press).
5. Zavos P M, Kaskar K, Correa J R, Sikka S C, "Seminal characteristics and sexual behavior in men of different age groups: Is there an aging effect?", *Asian J. Androl.* (2005) (in press).

affected by age is the percentage normal sperm morphology. Although there was a consistent decrease in the percentage normal sperm morphology as assessed by World Health Organization (WHO) guidelines<sup>6</sup> with increasing age, this decrease was more pronounced when employing strict morphology criteria.<sup>5</sup>

In summary, a number of factors that can cause or contribute to male infertility are:

- sexually transmitted diseases (STDs);
- fevers and infections;
- surgery of the reproductive tract;
- damage to the vas deferens (vasectomy);
- scrotal varicose veins (varicocele);
- use of depression or high blood pressure medications;
- exposure of the testes to high temperatures;
- use of tobacco, marijuana, or alcohol;
- medical conditions (diabetes);
- genetic or hormonal problems; and
- testicular injury.

#### Physical Examination

During physical examination, particular attention should be paid to the discerning features of hypogonadism. This would typically be viewed as poorly developed secondary sexual characteristics, eunuchoidal skeletal proportions, and the lack of normal male hair distribution. Testicular examination is essential and normal adult testes are 4.5cm long and 2.5cm wide on average, with a volume of approximately 20cc. Small and firm testes may signify damaged seminiferous tubules before puberty, whereas small and soft testes may suggest possible post-pubertal damage.

Epididymal irregularities suggest a previous infection and possible obstruction. Examination may reveal a small prostate with androgen deficiency or slight tenderness (bogginess) in men with prostatic infection. Any penile abnormalities like hypospadias, abnormal curvature, or phimosis, should be looked for. The scrotal contents should be carefully palpated with the patient in both the supine and standing positions. Varicoceles can often result in smaller left testes, and a discrepancy in size between the two testes should arouse suspicion. Both vas deferens should be palpated, as 2% of infertile men have congenital absence of the vas and seminal vesicles.

#### Routine Laboratory Testing

#### Semen Analysis

The initial test performed is a semen analysis, which allows the clinician to examine the sperm count, motility and morphology. The semen analysis results could provide vital information revealing the cause of the infertility. The parameters normally assessed during the evaluation are:

- Sperm count – normal range of 40 to 300 million sperm per milliliter with low sperm count (oligozoospermia) of fewer than 20 million per milliliter.
- Sperm motility – low sperm motility or movement (asthenozoospermia) may reduce the chances of conception, especially when paired with low sperm count – normal sperm motility of 50%.
- Sperm morphology – abnormally shaped sperm are often unable to swim effectively or penetrate the various oocyte investments during fertilization. A normal sperm has an oval head, slender midsection and a tail that beats in a wave-like motion.

Seminal specimens should be collected after three to four days of sexual abstinence via either masturbation or at intercourse. Seminal physical characteristics are also very important as they may indicate certain deficiencies.

#### Additional Laboratory Tests

Depending on the results of the semen analysis, more tests can be performed to diagnose specific causes of infertility. If the semen analysis shows clumping or signs of infection, a semen culture, prostate fluid culture and urinalysis may be ordered. Antisperm antibody testing may also be considered to evaluate potential immune system disorders. Fructose testing may reveal structural problems or blockage of the seminal vesicles. New studies suggest that sperm with certain levels of DNA fragmentation (sperm chromatin structural assay) serve as a strong predictor of reduced male fertility.<sup>6</sup>

When considering that the central component of laboratory testing is the semen analysis it must be insisted upon that this test is performed correctly. At collection the man is generally asked to obtain a specimen through masturbation. Special containers are also available for home collection, but prompt return of the specimen to the laboratory (within one hour) is

6. Spano M, Cordelli E, Leter G, Lombardo F, Lenzi A, Gandini L, "Nuclear chromatin variations in human spermatozoa undergoing swim-up and cryopreservation evaluated by the flow cytometric sperm chromatin structure assay", *Mol. Hum. Reprod.* (1999),5(1): pp. 29–37.

7. World Health Organization, WHO laboratory manual for the examination of human semen and semen cervical mucus interaction (6th Edit) Cambridge, UK, Cambridge University Press (1999).

**Table 1: Normal Values for Semen Parameters**

Parameter	Normal Values
Volume (ml)	2–6
Sperm concentration (million/ml)	>20
Motility (%)	>50
Forward progression (0–4)	>3
Normal morphology by WHO criteria (%)	>30
Normal morphology by strict criteria (%)	>14
Total sperm count (million)	>40
Total motile sperm (million)	>20
Total functional sperm (million)	>6

Source: World Health Organization (WHO).

mandatory. Table 1 lists normal standard values for adequate semen parameters as outlined by the WHO.<sup>7</sup>

It is important to note that these values are not the absolute values needed to achieve a pregnancy, but rather the statistical limits below which male infertility is more likely to be a problem. Due to significant variations in one or several semen parameters from one specimen to another, which are not uncommon, it is recommended that at least two semen specimens should be analyzed. Adherence to strict collection techniques and abstinence periods is therefore crucial to minimize variation and maximize accuracy.

## Ejaculation Difficulties

### Semen Collection

Semen specimens collected for evaluation should resemble the ejaculate delivered during intercourse, as closely as possible, if the male infertility factor is to be properly identified and treated.<sup>8,9</sup> The most accepted method of semen collection in humans for the purpose of semen analysis, artificial insemination (AI), or assisted reproductive technology (ART), is via masturbation.<sup>8,9</sup>

Since some males have difficulty in producing a seminal specimen via masturbation, recent developments have allowed semen collection to be performed via the use of semen collection devices (SCD). Those devices generally consist of non-spermicidal condoms made of polyurethane or silicone rubber.<sup>8,9</sup> Due to their acceptability by patients, lack of negative effects on sperm viability, and assistance in the improvement of

collected specimens to closely resemble the ejaculates obtained at intercourse, these devices may be used to better evaluate the male.

### Precoital Sexual Stimulation

It has also been demonstrated that ejaculates produced under increasing intensity of precoital sexual stimulation (PSS) can bring about significant increases in ejaculate characteristics.<sup>10</sup> PSS should therefore be considered during production of seminal specimens, particularly in patients with spermatogenic dysfunctions such as hypospermia, oligospermia, asthenospermia, or others.

### Erectile Dysfunction

Erectile dysfunction (ED) is the inability to attain and maintain penile erection sufficient to permit satisfactory intercourse and afflicts approximately 10% of the adult population of US men. This is increasingly evident in men who are asked to produce seminal specimens on demand for infertility evaluation and treatments. The inability to achieve penile erection is only part of the overall multifaceted process of male sexual function, which comprises various physical capabilities with important psychological and behavioral overtones. In addition, it should be recognized that sexual desire, orgasmic capacity and ejaculatory capacity might be intact in the presence of erectile dysfunction or may be deficient to some extent and contribute to the overall sexual dysfunction.

Recently, sildenafil citrate (Viagra®) has been considered as an effective treatment for erectile dysfunction (ED). Initial studies have shown that when Viagra is administered to men with ED, it can bring about erection and subsequent ejaculation. Various studies show a beneficial effect of Viagra with side effects that were not severe enough to discontinue treatment. It has been shown for the first time that not only does sildenafil citrate help males with erectile dysfunction, but also that the seminal characteristics of ejaculates produced at intercourse, along with semen preparation for use in subsequent intrauterine inseminations or ART, show normal values according to WHO criteria.<sup>11</sup>

8. Zavos P M, "Characteristics of human ejaculates collected via masturbation and a new Silastic seminal fluid collection device (SCD)", *Fertil. Steril.* (1985);43: pp. 491–492.

9. Zavos P M, Goodpasture J C, "Clinical improvements of specific seminal deficiencies via intercourse with a seminal collection device versus masturbation", *Fertil. Steril.* (1985);51: pp. 190–193.

10. Zavos P M, Correa J R, Kaskar K, Zarmakoupis-Zavos P N, "Precoital sexual stimulation and its effects on seminal characteristics", *Mid. East Fert. Soc. J.* (2003);8(1): pp. 1–5.

11. Zavos P M, Abou-Abdallah M, Kaskar K, Zarmakoupis-Zavos P N, "Erectile dysfunction: Seminal characteristics of men undergoing infertility treatment using Viagra", *Fertil. Steril.* (2003);80(3) supplement: S207.

## Treatment for Male Factor Infertility

Treatments for male infertility range from surgical intervention or intrauterine insemination (IUI) to various forms of ART, such as *in vitro* fertilization (IVF) or intracytoplasmic sperm injection (ICSI). Depending on the source of the problem, sperm can be taken from the man's ejaculate for use in assisted fertilization procedures.

With the advent of IVF and other modes of ART, the overall treatment of male infertility has changed dramatically. One treatment option for men who do have sperm in the ejaculate is intrauterine insemination (IUI). Intrauterine insemination is an infertility treatment in which sperm are placed directly into the female's uterine cavity near the time of ovulation. IUIs are commonly performed when there is a low sperm count or low motility. The sperm that will be injected during the procedure are prepared using a process called sperm washing.

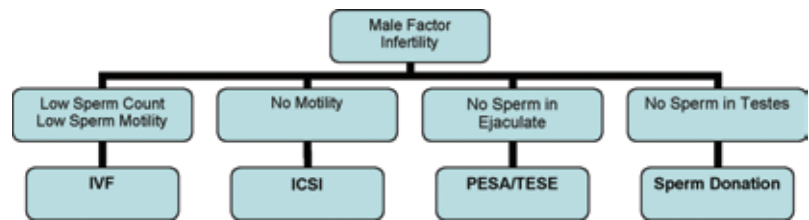
Since IUI is primarily used when there is very little or no male factor involved, a variety of ARTs are available for the male patient depending on the severity of the male factor (see *Figure 1*).

Patients who have suboptimal sperm counts (oligospermia) or motility (asthenospermia) in combination with a female factor should be advised to undergo IVF. Only  $100 \times 10^3$  motile sperm are needed per egg and the resulting embryos can be transferred directly into the uterine cavity of the female for subsequent implantation.

If only a few motile sperm are present with no forward progression, then the patient should be advised to have IVF in combination with ICSI. As opposed to conventional IVF, only one sperm is needed per egg, and is injected directly into the ooplasm. Confirmation of fertilization and transfer of embryos are similar to IVF.

If the patient presents with azoospermia, a testicular biopsy is needed to determine whether there are any sperm in the testes, in order to diagnose the azoospermia as either obstructive (does produce sperm) or non-obstructive (does not produce sperm). In cases of obstructive azoospermia, advanced sperm retrieval techniques, including testicular sperm aspiration (TESA), percutaneous sperm aspiration (PESA),

**Figure 1: Indications for the Various Types of Male Factor Infertility**



testicular microdissection, and testicular biopsy, combined with IVF and ICSI, now allow men with either a low sperm count or no sperm in their ejaculate the chance to produce a child.

- Testicular biopsy – an in-office surgical procedure in which several small pieces of testicular tissue are removed and examined for sperm which can be used in fertility procedures.
- TESA – a needle biopsy of the testicle in which a sample of tissue is taken directly from the testes and used to extract sperm for IVF or ICSI.
- PESA – a procedure involving a needle inserted into the epididymis in an effort to locate and aspirate a pocket of sperm.
- Testicular microdissection – involves careful surgical intervention in the testicle to locate any areas of potentially active spermatogenesis. This allows minimal extraction of testicular tissue, which minimizes the risk of permanent damage to the testicles.

For men whose testicular biopsy reveals complete azoospermia (non-obstructive), the use of donor sperm remains the best option for building a family. The use of donor sperm may also be considered when genetic screening indicates a possibility of passing on hereditary conditions such as cystic fibrosis to male offspring.

An increased understanding of male factor infertility and the recent advances made in assisted sperm retrieval techniques are now giving men who never thought they could have biological children the chance to father a child. Successful fertility outcomes at any reproductive center today remain the result of a combination of technological advances, scientific expertise and consistent andrological laboratory standards. ■